Neotropical Ichthyology

Original article

https://doi.org/10.1590/1982-0224-2026-0038

Gonadal development and anal fin morphogenesis in *Cnesterodon decemmaculatus* (Cyprinodontiformes: Poeciliidae)

Brian Jonathan Young[1,2], Gabriela Carina López[3,4], Diana Cristina Crespo[1], Pedro Carriquiriborde[5] and Gustavo Manuel Somoza[3,4]

Correspondence:
Brian Jonathan Young
brian.young@idaea.csic.es

This study characterizes the sexual development of the Neotropical poeciliid *Cnesterodon decemmaculatus*, a live-bearing fish, and examines the relationship between gonadal differentiation and anal fin morphogenesis. Histological analyses showed that gonadal differentiation occurs during gestation, with both ovaries and testes already differentiated at birth. Five gonadal developmental stages were identified for both sexes, spanning from newborn individuals to adults. Three stages of gonopodium development were also defined and compared with the anal fin morphology of undifferentiated individuals, and adult females. The earliest external signs of sexual dimorphism were detected at standard lengths of 9.32 mm in males and 16.1 mm in females. Males are identified earlier than females due to the differentiation of the gonopodial primordium. Finally, a Gonopodium Development Index (GDI) is proposed as a practical metric to quantify gonopodium morphogenesis independently of age. This index may represent a useful tool for studies of reproductive development and for applications in aquatic biomonitoring.

Keywords: Fish morphology, Gonadal histology, Gonopodium, Secondary sexual characteristics, Sex differentiation.

Submitted March 17, 2026
Accepted September 9, 2026
Epub ???, 2026

Associate Editor Elizete Rizzo
Section Editor Fernando Pelicice
Editor-in-chief José Birindelli

1 Instituto Nacional de Tecnología Agropecuaria (INTA), Instituto de Microbiología y Zoología Agrícola (IMYZA), Nicolás Reppetto 2751, B1686 Hurlingham, Argentina. (BJY) brian.young@idaea.csic.es (corresponding author), (DCC) dianacrespo56@yahoo.com.ar.

2 Institute of Environmental Assessment and Water Research (IDAEA-CSIC), Carrer Jordi Girona 18-26, 08034 Barcelona, Spain.

3 Instituto Tecnológico de Chascomús (CONICET-UNSAM), Chascomús, Argentina. (GCL) galo67@intech.gov.ar, (GMS) somoza@intech.gov.ar.

4 Escuela de Bio y Nanotecnologías (UNSAM), Chascomús, Argentina.

5 Centro de Investigaciones del Medioambiente (CIM), Facultad de Ciencias Exactas, Universidad Nacional de La Plata, CONICET, La Plata, Argentina. (PC) pcarriqu@quimica.unlp.edu.ar.

Online version ISSN 1982-0224
Print version ISSN 1679-6225

Neotrop. Ichthyol.
vol. 24, no. 4, 2026

El presente estudio caracteriza el desarrollo sexual de un poecílido neotropical, el pez vivíparo *Cnesterodon decemmaculatus*, y examina la relación entre la diferenciación gonadal con la morfogénesis de la aleta anal. Los análisis histológicos mostraron que la diferenciación gonadal ocurre durante la gestación, con ovarios y testículos ya diferenciados al nacer. Se identificaron cinco estadios gonadales para el desarrollo ovárico y testicular desde individuos recién nacidos hasta adultos. Además, se definieron tres estadios de desarrollo para el gonopodio y se compararon con la aleta anal de individuos indiferenciados y de hembras adultas. Los primeros signos externos de dimorfismo sexual se detectaron a partir de longitudes estándar de 9,32 a 16,1 mm en machos y hembras, respectivamente. Los machos se identifican antes que las hembras debido a la diferenciación del primordio gonopodial. Finalmente, se propone un Índice de Desarrollo de Gonopodio (IDG) como métrica práctica para cuantificar la morfogénesis del gonopodio independientemente de la edad. Este índice puede ser una herramienta útil para estudios del desarrollo reproductivo y aplicaciones en biomonitoreo acuático.

Palabras clave: Caracteres sexuales secundarios, Diferenciación sexual, Gonopodio, Histología gonadal, Morfología de peces.

INTRODUCTION

Teleost fish exhibit a great diversity of reproductive modes (Trudeau, 2022) and a variety of sex determination and differentiation mechanisms (Nagahama *et al*., 2020). Also, several gonadal differentiation and development patterns have been described in gonochoristic and hermaphroditic species (Trudeau, 2022). Reproduction in teleosts is a complex process regulated by the hypothalamic-pituitary-gonadal axis (Devlin, Nagahama, 2002; Vissio *et al*., 2021) and it is also known that hormonal and/or environmental factors play key roles during gonadal sex differentiation (Fernandino *et al*., 2012; Zohar *et al*., 2021). Hormones affect the process of sexual differentiation during development, inducing the manifestation of secondary sexual characteristics that express the anatomical, physiological, and behavioral differences between the sexes (Mei, Gui, 2015). Because of the diversity of teleost fish, gonadal development has been extensively studied both in females (Lubzens *et al*., 2010) and males (Schulz *et al*., 2010; Uribe *et al*., 2015).

In teleost, viviparity is unique compared to other vertebrates because it involves the ovary as a gestational organ (Uribe *et al*., 2019), and in different viviparous species, sex is determined before birth (Kramer, Kallman, 1985; Koya *et al*., 2003). Among teleosts, the family Poeciliidae includes many viviparous species (Uribe *et al*., 2019). These fishes are also interesting because they present a clear sex dimorphism; adult males are usually smaller than females, and their anal fin is modified in a gonopodium, which is used to transfer sperm bundles into the female genitalia during copulation (Parenti *et al*., 2010; Uribe *et al*., 2019). It is also known that the development of the gonopodium is regulated by androgens secreted by the testis during gonadal development (Ogino *et al*., 2004, 2018) and that steroidogenic activity in gonadal tissue occurs in very early

sexual development (Schreibman *et al*., 1982; Blasco *et al*., 2013; Castañeda-Cortés *et al*., 2020). Therefore, histological and morphological biomarkers in poeciliids can be used as indicators of endocrine disruption (Doyle, Lim, 2002; Angus *et al*., 2005; Jackson *et al*., 2019; Zhang *et al*., 2023; Huang *et al*., 2024).

Cnesterodon (Cyprinodontiformes, Poeciliidae) is a genus phylogenetically related to *Gambusia*, *Xiphophorus*, and *Poecilia* (Hrbek *et al*., 2007). *Cnesterodon decemmaculatus* is a Neotropical fish species characteristic of the Río de la Plata basin (Ramos-Fregonezi *et al*., 2017). Its gonadal morphology and histology have been originally described in adult fish (Siccardi, 1955; Sotelo, Trujillo-Cenóz, 1958; Parenti *et al*., 2010; Santamaría-Martín *et al*., 2021). In addition, the morphology of the gonopodium in adult males was documented by Lucinda, Reis (2005). However, there is a gap in knowledge of gonadal development and gonopodial morphogenesis, and their relationship from early stages.

Cnesterodon decemmaculatus has been widely used in many biological studies (Ramos-Fregonezi *et al*., 2017; Parenti *et al*., 2010; Zambrano *et al*., 2023). Due to its tolerance to environmental pollution and abundance in polluted aquatic environments, in addition to the ease with which it can be kept in captivity, this species has been widely used in field and laboratory ecotoxicological studies (Carriquiriborde *et al*., 2007; Candioti *et al*., 2010; Baudou *et al*., 2021). In particular, some studies have demonstrated that the endocrine disruptor ethynilestradiol can alter gonadal histology, male-to-female sex ratio, and gonopodium morphology in juvenile and adult fish (Young *et al*., 2020, 2017; Vidal *et al*., 2018). Therefore, it is important to know normal gonadal and gonopodial development and their relationship for a correct interpretation of these phenomena. In this context, the aim of the present study was a) to describe the gonadal development and anal fin morphogenesis, b) to assess the relationship between these two processes, and c) to elaborate a quantitative index that describes the degree of gonopodial development.

MATERIAL AND METHODS

Fish. *Cnesterodon decemmaculatus* specimens were reared at the fish facility of the Instituto Nacional de Tecnología Agropecuaria (INTA), Argentina. Taxonomic classification was performed using the ichthyology collection CFA2163 of the Félix de Azara Natural History Foundation (Buenos Aires, Argentina) as reference material, following Paracampo *et al*. (2020). Newborn larvae were obtained from adult fish reared in tanks in a room maintained at 23 ± 2°C and a photoperiod of 16:8 (L:D) h. Tap water was dechlorinated and maintained with gentle aeration. Fish were fed daily *ad libitum* with crushed commercial fish food (Shulet®, Argentina) and *Daphnia magna* neonates. Organic material was periodically siphoned from the bottom of the recipients.

Experiments. After birth, newly born larvae were kept in 4-L glass aquaria, and the number of larvae and birth date were recorded. Fish were sampled weekly from birth to 140 days after birth (dab) to characterize gonadal development and the anal fin.

Gonadal histology. Gonadal development was examined histologically. Fish were anesthetized in ice-cold water, and then the whole larvae were fixed in Bouin's fluid at

4°C. Fixed samples were dehydrated, embedded in Paraplast®, cut into 6 µm transverse sections, and serially mounted. The histological sections were stained with hematoxylin and eosin. The preparations were observed and photographed with a digital camera (Nikon DS-Fi1) using a microscope (Nikon Eclipse E600). Pictures were processed using the software NIS-Elements F 3.00.

Somatic growth and secondary sexual characteristics. Fish used for morphometric measurements were anesthetized by immersion in ice-cold water and, when possible, sexed according to secondary sexual characters. In early developmental stages, external sex identification was not possible because sexually dimorphic traits had not yet developed. Then, fish were observed and measured at a stereomicroscope. After examination and measurement, fish were returned to the rearing aquaria. Fish selected for histological analyses or *in toto* staining were euthanized with an overdose of benzocaine prior to fixation and processing. Somatic growth was characterized by standard length (SL) and fresh weight (W). Complementary, condition factor (*K*) was calculated as shown:

$$K = W(mg)\text{x}100 \,/\, \text{SL}(mm)^3 \qquad \text{Equation 1}$$

The measured secondary sexual characters were the length of rays 4 and 6 of the anal fin (R4 and R6, respectively). Morphological parameters such as SL, R4, and R6 were measured using an electronic digital caliper with a precision of 0.1 mm. Fish were weighed out using a digital scale with a precision of 0.2 mg. A double staining with Alizarin-Red and Alcian-Blue was carried out using the protocol described by Chalde *et al*. (2011), which was used to visualize bone and cartilaginous structures, respectively. The morphological structure of the anal fin was observed and photographed with a digital camera (Evolution BF) using a stereomicroscope (Nikon SMZ800). Micrographs were processed using the software Image-Pro Plus 4.5.

Numerical indices. A database was created using 400 fish of different ages (0-538 dab). The anal fin morphogenesis was followed during sexual development. Several parameters were recorded in male and female fish to detect the main variables of sexual dimorphism. R4 was selected because it undergoes pronounced elongation during gonopodial development and has been previously used in morphometric indices of different poeciliid species (Angus *et al*., 2001; Doyle, Lim, 2002; Young *et al*., 2020). R6 was used as a reference ray because its length increases mainly with body growth and does not exhibit the marked elongation observed in rays 3–5 during gonopodial morphogenesis. For this purpose, an elongation index (EI) and a gonopodial index (GI) were calculated as shown in Equations 2 and 3, respectively.

$$EI = R4 \,/\, R6 \qquad \text{Equation 2}$$

$$GI(\%) = R4 \,/\, SL \text{ x } 100 \qquad \text{Equation 3}$$

Four stages of development of the gonopodium were defined considering the main descriptors of this process: EI, GI, presence or absence of a gonopodial primordium (GP), and the presence of serraes, hooks, and cirrus (SHC). The relative frequency of

each gonopodium developmental stage was related to SL and age.

A novel Gonopodium Developmental Index (GDI) was elaborated using the main descriptors of the gonopodium development. The qualitative parameters were transformed into quantitative parameters through numerical constants. These were 0.3 and 0.25 for the presence of GP and SHC, respectively. Average values and the lower and upper limits of each stage were defined. Finally, the model's potency was validated according to its predictive efficiency on fish not used in the database: the number of successes were expressed as a percentage based on a total of 49 specimens.

The numerical model is based on the correlation between GI and EI (Fig. **S1**A). However, this relationship does not allow clear-cut segregation between stages of gonopodium development and sexes to be distinguished. Therefore, two qualitative parameters were introduced to transform both GI and EI: the appearance of GP and SHC at the end of the anal fin (Eq. 4 and 5). These qualitative parameters were transformed into quantitative values. Then, an iterative process was employed to determine the value that most accurately explained the separation between groups. A value of 0.3 was assigned to the appearance of GP (coefficient α), and a value of 0.25 to the appearance of SHC (coefficient β). Since there is a linear function between the transformed variables GI_t and EI_t with $R^2 = 0.97$ (Fig. **S1**B), GDI was calculated after applying the logarithm to the sum of these transformed variables, as shown in Eq. 6. Finally, the model was then represented by Eq. 7, where Eq. 4 and 5 are replaced in Eq. 6, generating the final GDI.

$$EI_t = EI + \alpha + 4\beta \qquad \text{Equation 4}$$

$$GI_t = GI/100 + 0.4\alpha + \beta \qquad \text{Equation 5}$$

$$GDI = log(GI_t + IE_t) \qquad \text{Equation 6}$$

$$GDI = log(GI/100 + 1.4\alpha + 5\beta + EI) \qquad \text{Equation 7}$$

Statistical analysis. Descriptive statistics were conducted to summarize and describe the characteristics of each dataset. In addition, a Spearman correlation matrix was performed to assess the relationship between variables. The data were analyzed using Infostat® (v. 1.0) and GraphPad Prism® (v. 5.01).

RESULTS

Testis development. This process was characterized by five stages, summarized in Tab. 1 and illustrated in Fig. 1. These stages encompass the transformation of paired testicular primordia into a single fused testis, the progressive differentiation of the spermatogenic line, the development of sperm and efferent ducts, the appearance of the eosinophilic substance ("pink-protein"), and the formation and accumulation of spermatozeugmata within the efferent duct. To facilitate the visualization of germ cell development, representative high-magnification micrographs of spermatocytes, spermatids, and spermatozeugmata are provided in Figs. 1I, J, and K, respectively.

TABLE 1 | Stages of the testicular development in *Cnesterodon decemmaculatus*.

Stage	Histological characteristics	Histological image / standard length histogram
1	• Two paired testicular structures joined to the mesentery by a central septum in the dorsal part of the body cavity, below the swim bladder. • Somatic cells and blood vessels in the center of the gonad. • Cysts containing spermatogonia at the periphery of each paired testicular structure. • Fish size in this stage ranged between 6.16 and 8.43 mm with an average of 7.23 mm.	Figs. 1A–B
2	• Presence of sperm ducts in each paired testicular structure. • Increase in the size of the paired testicular structures (elongation). • Fish size ranged between 7.07 and 10.03 mm with an average of 8.62 mm.	Figs. 1C–D
3	• Fusion of the paired testicular structures into a single testis and formation of a central spermatic duct. • Disappearance of the central septum. • Different spermatogenetic stages are observed, except spermatozoa. • Cysts containing spermatogonia located on the periphery of the testis. • Fish size ranged between 8.96 and 15.40 mm with an average of 11.65 mm.	Figs. 1E–F
4	• Presence of an eosinophilic substance (commonly called “pink-protein”) in the efferent ducts. • Spermatozoa grouped into spermatozeugmata are observed but they have not yet filled the lumen of the efferent ducts. • Fish size ranged between 14.10 and 17.08 mm with an average of 15.86 mm.	Figs. 1G–H
5	• Testis comprises approximately 2/3 of the body cavity. • Efferent ducts contain many spermatozeugmata surrounded by the “pink protein”. • Spermatozoa are arranged into discrete sperm bundles, with their heads oriented peripherally and their flagella directed toward the center of the spermatozeugmata. • Cysts containing other spermatogenetic stages are reduced to the periphery of the testis. • Fish size ranged between 14.30 and 23.52 mm, averaging 19.20 mm.	Figs. 1L–M

Ovarian development. This process was histologically described in five stages, summarized in Tab. 2 and illustrated in Fig. 2. These stages comprise the transformation of paired ovarian structures into a single saccular ovary through the formation and closure of the ovarian cavity, alongside the progressive differentiation of the oogenic line, from oogonia and primary oocytes to cortical alveoli and vitellogenic oocytes. To facilitate the visualization of oogenic development, representative high-magnification micrographs of oogonia, primary oocytes, and cortical alveoli oocytes are provided in Figs. 2G, H, and I, respectively.

Anal fin morphogenesis. The anal fin of *C. decemmaculatus* was differentiated into five stages (Fig. 3), involving a series of morphological changes that can be summarized according to the following characteristics:

Undifferentiated anal fin (UAF): at this stage, fish cannot be sexed by external morphological characteristics. The anal fin has ten rays organized in a semi-lobar shape. Rays 4 to 10 were caudally divided into anterior and posterior sections. Additionally, the number of segments of each ray is shown in Tab. **S2**. All fish presented these morphological characteristics from birth to the gonopodial differentiation period. The light red color of the rays was due to a slight ossification (Fig. 3A). The observed frequencies of SL were fitted to a gamma-type distribution (Fig. 3B). Sexually undifferentiated fish (n = 175) were observed from birth to 59.5±46.2 dab, presenting an average GI of 21.9±1.8%, EI of 1.05±0.05, and SL of 10.5±3.4 mm.

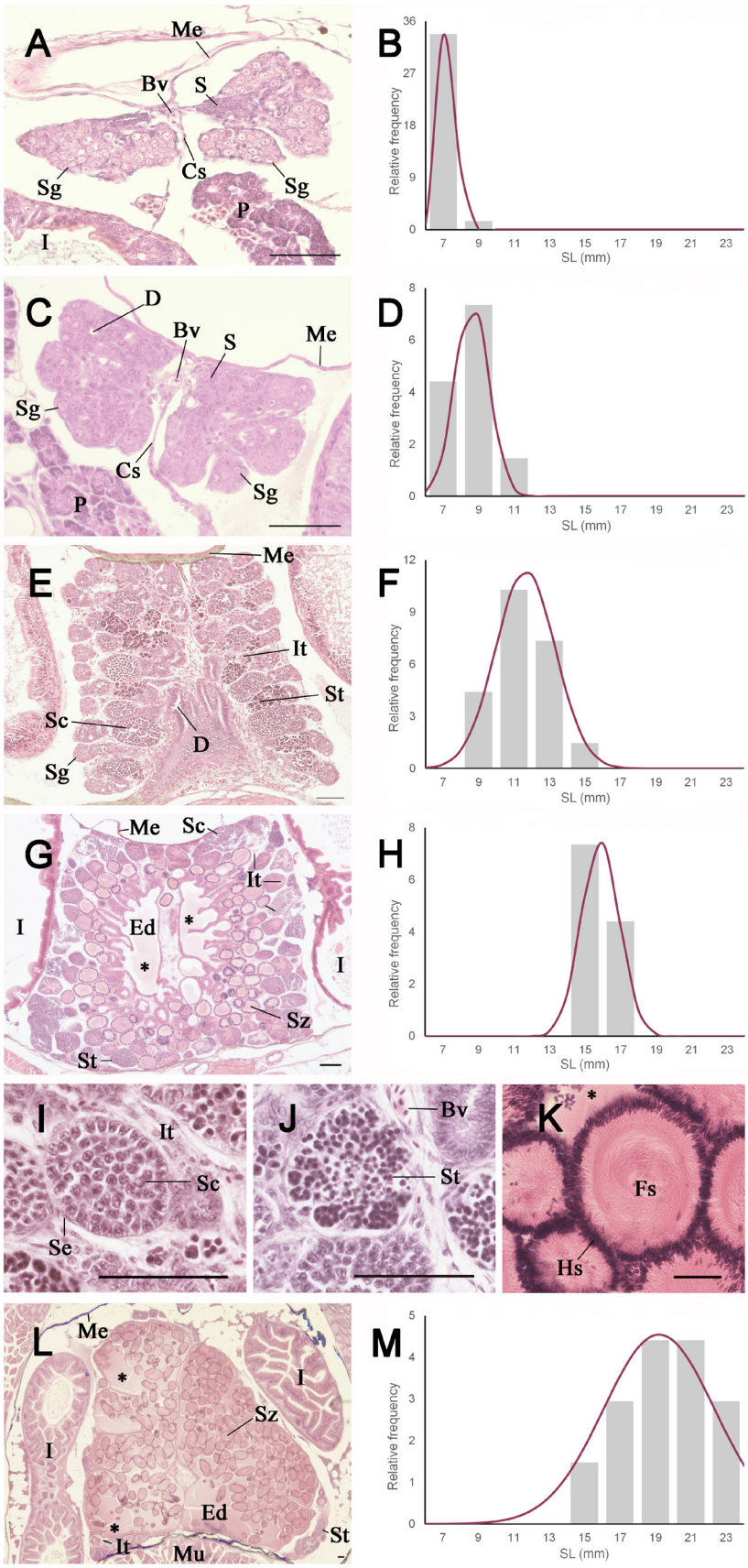

FIGURE 1 | Testis development from parturition to adulthood in *Cnesterodon decemmaculatus*. Each gonadal stage is shown (**A-C-E-G-L**) together with the standard body length (SL) frequency histogram (**B-D-F-H-M**). Different spermatogenic stages are shown, including spermatocyte cyst (**I**), spermatid cyst (**J**), and spermatozeugmata (**K**). Me: mesentery; Bv: blood vessels; S: testicular somatic cells; D: sperm ducts; Cs: central septum; Sg: spermatogonia cyst; Sc: spermatocyte cyst; St: spermatid cyst; Sz: spermatozeugmata; Hs: Heads of spermatozoa; Fs: Flagella of spermatozoa; Se: Sertoli cells; Ed: efferent ducts; It: interstitial tissue; P: pancreas; I: intestine; Mu: muscle. An asterisk represents an area stained by an eosinophilic substance ("pink-protein"). Scale bar = 50 µm.

TABLE 2 | Stages of the ovarian development in *Cnesterodon decemmaculatus*.

Stage	Histological characteristics	Histological image / standard length histogram
1	• Two paired ovarian structures attached to the mesentery in the dorsal part of the body cavity, below the swim bladder. • In all cases, at least one primary oocyte and some oogonia were observed, characterized by their spherical/ovoid shape, containing a large central nucleus, a nucleolus, and dispersed fibrillary and granular material, surrounded by a clear cytoplasm. • Fish size in this stage ranged between 6.60 and 7.30 mm with an average of 6.93 mm.	Figs. 2A–B
2	• Centripetal growth of a group of somatic cells in the dorsal-lateral region of each ovarian structure. The ovarian cavity is formed after the fusion of these cells. • Increase in the number of primary oocytes and oogonia. • Fish size ranged between 6.86 and 8.77 mm with an average of 7.91 mm.	Figs. 2C–D
3	• Closure of the ovarian cavity in the dorsal region of the ovary and fusion of both ovarian structures into a single saccular ovary. • Increase in the number of oogonia and primary oocytes, together with the first appearance of cortical alveoli oocytes. • Fish size ranged between 7.41 and 11.98 mm with an average of 9.45 mm.	Figs. 2E–F
4	• Enlargement of the ovary as a single saccular structure. • Ovarian cavity occupies most of the mid-dorsal region of the ovary. • Numerous oogonia, primary oocytes and cortical alveoli oocytes surrounding the ovarian cavity. • Fish size ranged between 9.42 and 21.00 mm with an average of 14.91 mm.	Figs. 2J–K
5	• Presence of vitellogenic oocytes and the simultaneous occurrence of all major oogenetic stages, including oogonia, primary oocytes, cortical alveoli, and vitellogenic oocytes. • Fish size ranged between 20.10 and 31.02 mm, averaging 26.12 mm.	Figs. 2L–M

Gonopodial Stage 1 (GS1): this stage was characterized by the thickening of ray 3 and the beginning of the elongation of rays 3, 4, and 5, forming the GP (Fig. 3C). Values of SL ranging between 7.8 (21 dab) and 19.1 mm (274 dab) were recorded. The observed frequencies of SL of males in GS1 showed a normal distribution (Fig. 3D). This stage was found in fish (n = 60) averaging an age of 104.7±58.2 dab, with a GI average of 24.3±2.9%, EI of 1.26±0.13, SL of 13.9±2.7 mm, and age of 104.7±58.2 dab.

Gonopodial Stage 2 (GS2): it was characterized by a progressive allometric elongation of rays 3, 4, and 5 to rays 6, 7, and 8. However, there is neither a complete ossification of the rays nor the presence of serraes, hooks, and cirrus (Fig. 3E). Values of SL ranging between 12.6 (45 dab) and 20.8 mm (274 dab) were recorded. The observed frequencies of SL of males in GS2 showed a normal distribution (Fig. 3F). These fish presented a significant increase in GI with average values of 40.5±5.2%, EI of 2.08±0.31, SL of 16.6±1.8 mm and age of 106.0±41.9 dab (n = 24).

Gonopodial Stage 3 (GS3): the gonopodium is characterized by a complete ossification of the rays, the presence of serraes, hooks, and cirrus at the distal end, thickening of the end of ray 6, ankylosis at the base of all rays, and the loss of rays 9 and 10 (Fig. 3G). Specifically, a cirrus at the end of ray 3, serraes in the anterior and posterior sections of ray 4, and hooks in the anterior and posterior sections of ray 5 were observed. A detail of these structures at the distal tip of the gonopodium is shown in Fig. 3H. In addition, the number of segments of each ray in a fully mature gonopodium is shown in Tab. **S2**. Values of SL ranging between 13.8 (55 dab) and 23.5 mm (274 dab) were recorded. The SL frequencies of males in GS3 presented a normal distribution (Fig. 3I). These fish (n = 93) presented an average GI of 41.5±3.9%, EI of 2.25±0.17, SL of 19.4±1.8 mm, and age of 193.4±65.4 dab.

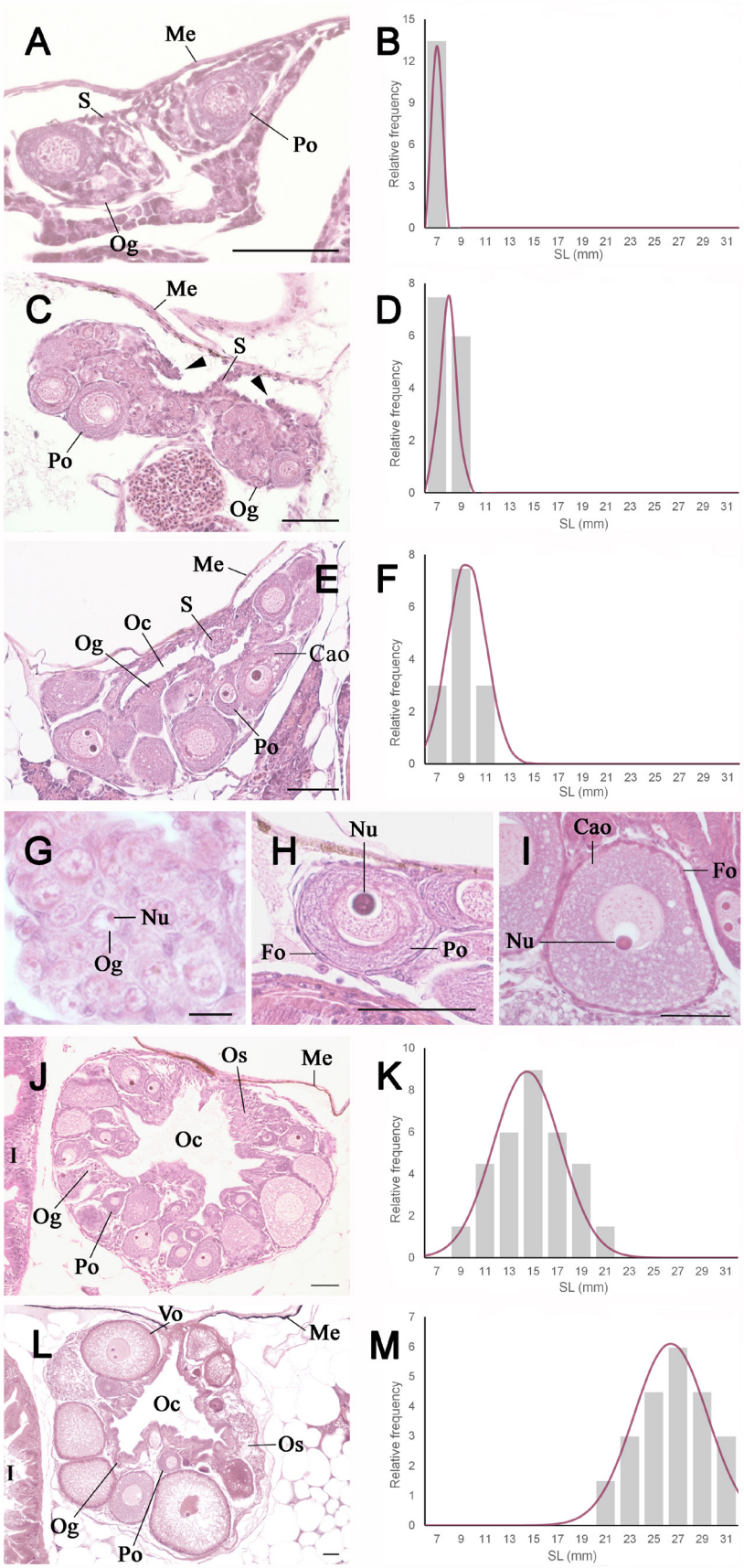

FIGURE 2 | Ovary development from parturition to adulthood in *Cnesterodon decemmaculatus*. Each gonadal stage (**A-C-E-J-L**) together with the standard body length (SL) frequency histogram (**B-D-F-K-M**). Different oogenic stages are shown, including oogonia (**G**), primary oocyte (**H**), and cortical alveoli oocyte (**I**). Me: mesentery; Og: oogonia; Po: primary oocyte; S: somatic ovarian cells; Fo: follicular cells; Nu: oocyte cell nucleus; Oc: ovarian cavity; Cao: cortical alveoli oocyte; Os: ovarian stroma; Vo: vitellogenic oocyte; P: pancreas; I: intestine. Arrowheads indicate the location of a group of centripetally growing somatic cells in the dorsal region of the ovary. Scale bar represent 50 µm, except in Fig. 2G, where the scale bar represents 10 µm.

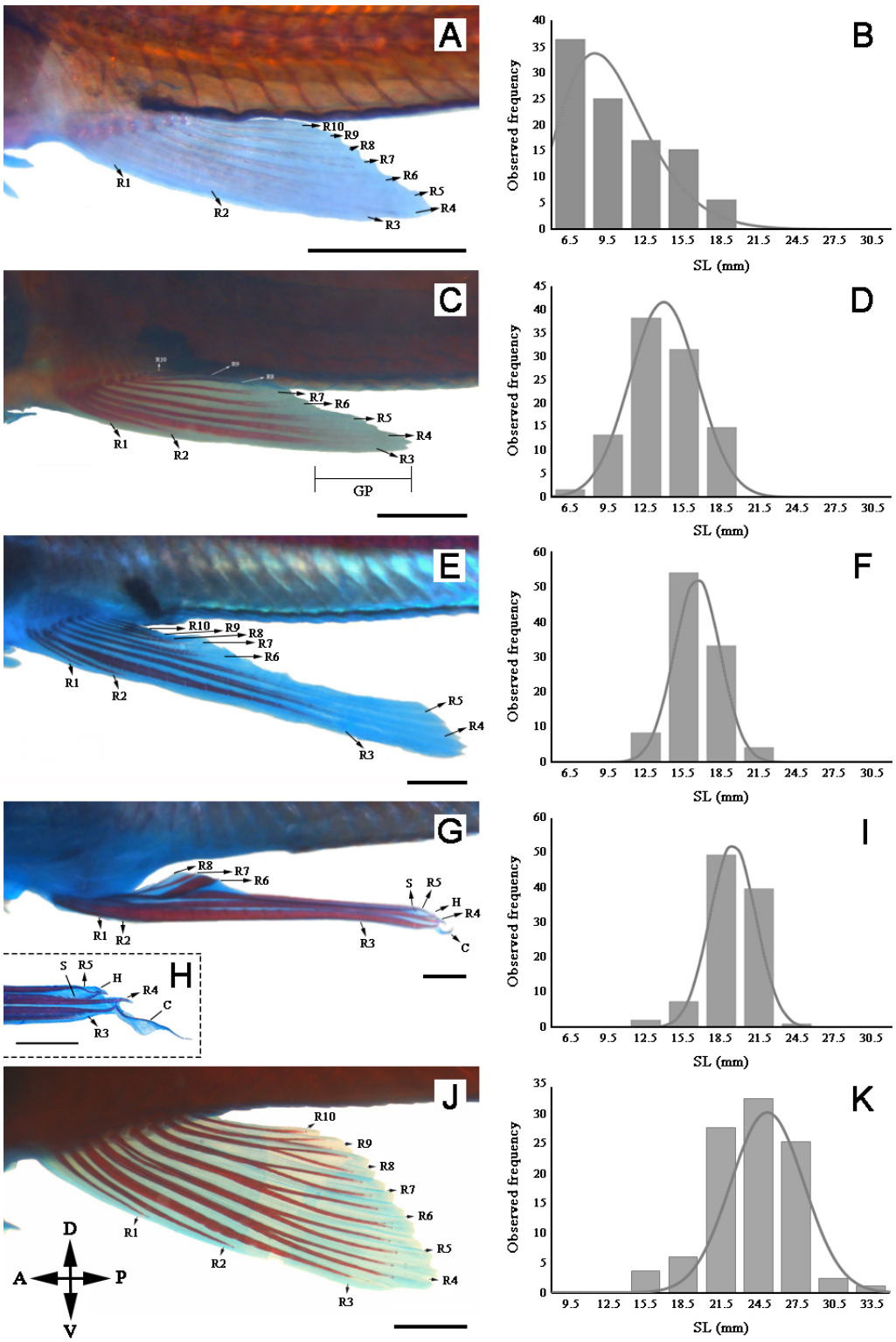

FIGURE 3 | Anal fin morphogenesis in *Cnesterodon decemmaculatus* male and female stained *in toto*. Specimens were double-stained with Alizarin Red and Alcian Blue to visualize bony and cartilaginous structures, respectively (**A-C-E-G-H-J**). Frequency histogram of standard length (SL) for each stage of anal fin morphogenesis (**B-D-F-I-K**). **A-B**: Undifferentiated Anal Fin. **C-D**: Gonopodial Stage 1. **E-F**: Gonopodial Stage 2. **G-I**: Gonopodial Stage 3. **H**: Distal end of the fully developed gonopodium. **J-K**: Adult Female Anal Fin. Fin ray (R) numeration increases in the ventral-dorsal direction. A: anterior; P: posterior; V: ventral; D: dorsal; S: serrae; H: hook; C: cirrus. Arrows indicate each ray (R) and its respective numbering increases in the ventral-dorsal way. Scale bar = 1 mm.

Adult female anal fin (AFAF): the anal fin of adult females did not present different morphological structures compared to a sexually undifferentiated fish, except for the degree of ray ossification and size (Fig. 3J). Females with these characteristics were recorded with SL values from 16.1 (70 dab) to 32.7 mm (538 dab). The SL frequency of females was fitted to a normal distribution (Fig. 3K). These fish presented an average GI of 18.2±2.5%, EI of 1.13±0.07, SL of 24.1±3.3 mm, and age of 227.4±147.4 dab (n = 82).

Relationship between the gonadal development, anal fin morphogenesis, and body size. The integrated analysis of gonadal development, anal fin morphology, and body size allowed the identification of three distinct sexual groups based on external characters and size-related parameters: sexually undifferentiated fish, males, and females (Tab. 3; Fig. 4). Descriptive statistics of morphological parameters, age, and indices for each anal fin category, including GDI, are summarized in Tab. 4, while the distribution of gonadal development stages (Stages 1–5) across anal fin categories is shown in Fig. 4. Additionally, relationships between SL and R4, GI, and EI across different sexual phenotypes are presented in Fig. **S3**.

In the range between 12.5 and 15.5 mm of SL, a marked dimorphism in EI was observed. In this range, 100% of the females had an ovary in Stage 4, while 50% of the males had a testis in Stage 3, 25% in Stage 4, and 25% in Stage 5. Additionally, the male-to-female sex ratio determined by histology was 58.5:41.5 (n = 130), suggesting a balanced sex ratio. In both sexes, gonadal development showed a stronger association with body size than with age. Individuals exhibiting an undifferentiated anal fin (UAF) were generally smaller (median SL = 9.7 mm) and displayed low GDI values (≤ 0.18). This group comprised individuals of both sexes at early gonadal stages (Stages 1–3) (Fig. 4), corresponding to sexually undifferentiated fish based on external morphology.

Males were characterized by the presence of a modified anal fin (GS1-GS3) and GDI values consistently higher than 0.20 (Tab. 4). Across gonopodial stages, SL increased progressively, accompanied by a marked increase in GDI, reflecting the advancement of gonopodium development. Gonadal examination indicated that individuals in this group predominantly possessed testes across progressive stages of gonadal development (Stages 1-5), with advanced testicular stages prevailing at later gonopodial stages (Fig. 4).

TABLE 3 | Criteria for determining the sexual phenotype of *Cnesterodon decemmaculatus*. GP: gonopodial primordium; GI: gonopodial index; EI: elongation index; SL: standard length; W: body weight; R4: length of ray 4 of the anal fin; R6: length of ray 6 of anal fin.

Sexual phenotype	Characteristics
Undifferentiated sex	• Absence of GP and SL < 16.1 mm
Male	• Presence of GP • GI > 21% and EI > 1.25 • GI > 28% • EI > 1.36
Female	• Absence of GP and SL > 16.1 mm • W > 85 mg and GI < 23% or EI < 1.15 • EI < 1.36 and R4 > 4.6 mm or R6 > 3.8 mm • GI < 24% and SL > 16.1 mm

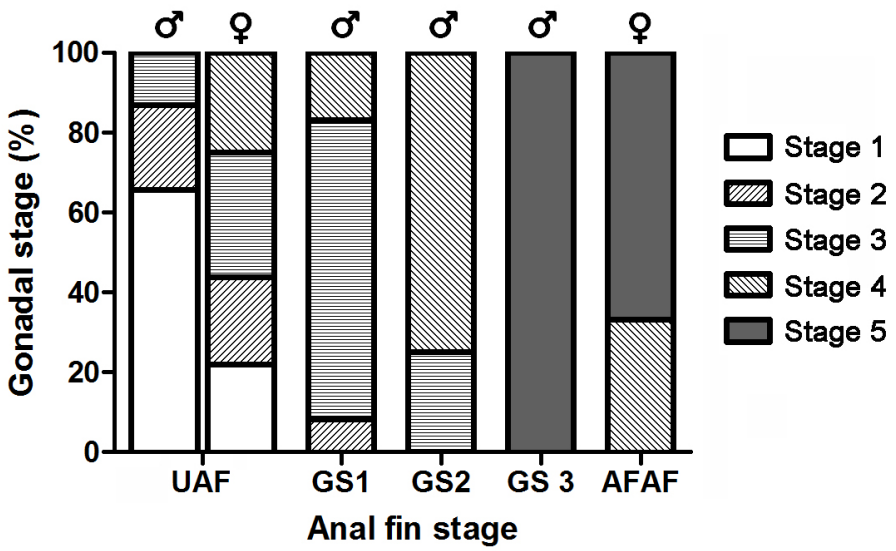

FIGURE 4 | The observed frequency of gonadal stages for each anal fin stage in male and female *Cnesterodon decemmaculatus*. Stages 1-5: Gonadal stages; UAF: Undifferentiated anal fin; GS: Gonopodial Stage; AFAF: Adult female anal fin.

Females were characterized by the presence of an unmodified anal fin (AFAF), low GDI values (< 0.20), and larger body sizes (median SL = 24.5 mm). Individuals within this group presented ovaries, predominantly at advanced gonadal development stages (Stages 4–5; Fig. 4).

Based on these patterns, external morphological traits combined with body size provided clear criteria for sex prediction. GDI incorporates EI, GI, and the presence of a gonopodial primordium (GP) and serraes, hooks and cirrus (SHC), with higher values reflecting advanced gonopodial development (Fig. 5). To facilitate practical classification, a decision framework can be applied, as summarized in Fig. 6:

- Males: fish with GDI > 0.19.
- Females: fish with GDI ≤ 0.19 and SL > 16.1 mm.
- Sexually undifferentiated fish: individuals with GDI < 0.19 and SL < 16.1 mm.

For individuals close to the threshold values (GDI ≈ 0.19 or SL ≈ 16.1 mm), multiple characters including anal fin morphology and body size should be jointly considered to reduce potential misclassification.

Additionally, a non-linear relationship was observed between SL and W (Fig. **S4**). The values of R4 and R6 were positively correlated with W (R = 0.84 and 0.77, respectively; $p \leq 0.01$). Particularly in male fish, both SL and W values showed positive correlations with R4 (R = 0.86 and 0.83, respectively) and R6 (R = 0.87 and 0.92, respectively) (n = 191; $p \leq 0.01$).

TABLE 4 | Descriptive statistics of morphological parameters, age and indices for each anal fin category (n = 434). SL: standard length; R4: ray 4 of the anal fin; R6: ray 6 of the anal fin; W: body weight; GI: gonopodial index; EI: elongation index; *K*: condition factor; GDI: gonopodium development index.

Anal fin category	Descriptor	Age (d)	SL (mm)	R4 (mm)	R6 (mm)	W (mg)	GI (%)	EI	K	GDI
Undifferentiated Anal Fin (UAF)	Mean (± SD)	59.5 ± 46.2	10.5 ± 3.4	2.3 ± 0.7	2.2 ± 0.6	14.8 ± 13.1	21.9 ± 1.8	1.05 ± 0.05	1.45 ± 0.23	0.10 ± 0.02
	Median	50	9.7	2.2	2.0	9.8	21.7	1.04	1.45	0.10
	Minimum	0	6.2	1.3	1.3	2.7	16.6	0.91	0.96	0.05
	Maximum	216	18.0	4.2	3.7	59.0	27.6	1.24	2.07	0.18
Gonopodial Stage 1 (GS1)	Mean (± SD)	104.7 ± 58.2	13.9 ± 2.7	3.4 ± 0.9	2.7 ± 0.5	35.1 ± 21.6	24.3 ± 2.9	1.26 ± 0.13	1.53 ± 0.18	0.28 ± 0.04
	Median	89	13.9	3.3	2.7	26.9	23.6	1.24	1.52	0.28
	Minimum	21	7.8	1.8	1.3	9.3	19.1	1.05	1.07	0.22
	Maximum	274	19.1	5.6	3.6	93.4	33.2	1.59	1.93	0.36
Gonopodial Stage 2 (GS2)	Mean (± SD)	106.0 ± 41.9	16.6 ± 1.8	6.7 ± 1.1	3.4 ± 0.4	68.8 ± 19.0	40.5 ± 5.2	2.08 ± 0.31	1.57 ± 0.14	0.46 ± 0.05
	Median	99	16.8	6.9	3.3	68.8	41.4	2.11	1.59	0.47
	Minimum	45	12.6	4.7	2.6	34.8	30.0	1.64	1.32	0.38
	Maximum	274	20.8	8.5	4.1	100.6	51.8	2.59	1.87	0.54
Gonopodial Stage 3 (GS3)	Mean (± SD)	193.4 ± 65.4	19.4 ± 1.8	8.0 ± 0.9	3.7 ± 0.5	91.8 ± 30.2	41.5 ± 3.9	2.25 ± 0.17	1.39 ± 0.16	0.64 ± 0.02
	Median	206	19.3	8.0	3.7	89.5	41.1	2.25	1.36	0.64
	Minimum	55	13.8	6.3	2.5	35.4	32.5	1.88	1.12	0.60
	Maximum	274	23.5	10.1	5.0	170.4	54.6	2.68	1.73	0.68
Adult Female Anal Fin (AFAF)	Mean (± SD)	227.4 ± 147.4	24.1 ± 3.3	4.4 ± 0.8	3.9 ± 0.8	297.8 ± 173.1	18.2 ± 2.5	1.13 ± 0.07	1.82 ± 0.34	0.12 ± 0.02
	Median	140	24.5	4.2	3.6	294.0	18.1	1.12	1.73	0.12
	Minimum	70	16.1	2.9	2.7	70.6	13.2	1.00	1.26	0.07
	Maximum	538	32.7	6.0	5.6	779.1	23.5	1.35	3.14	0.19

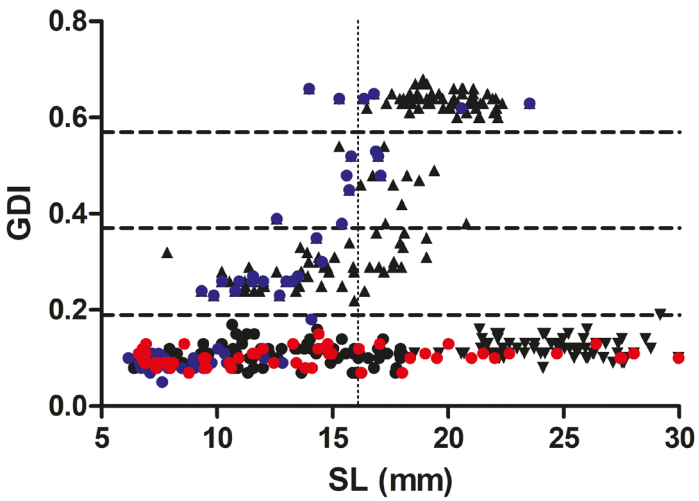

FIGURE 5 | Values of the Gonopodium Development Index (GDI) were obtained for male and female fish at different body sizes (SL). Phenotypic sexes are represented by black dots undifferentiated anal fin (UAF), triangles male (presence of the gonopodium), and inverted triangles adult female anal fin (AFAF). Blue and red dots represent male and female fish as corroborated by histology, respectively. Horizontal cut lines indicate the separation between the different stages in GDI values equal to 0.19; 0.37 and 0.57. The vertical cut line indicates the body size from which it is possible to differentiate phenotypically between female UAF and AFAF (SL=16.1 mm).

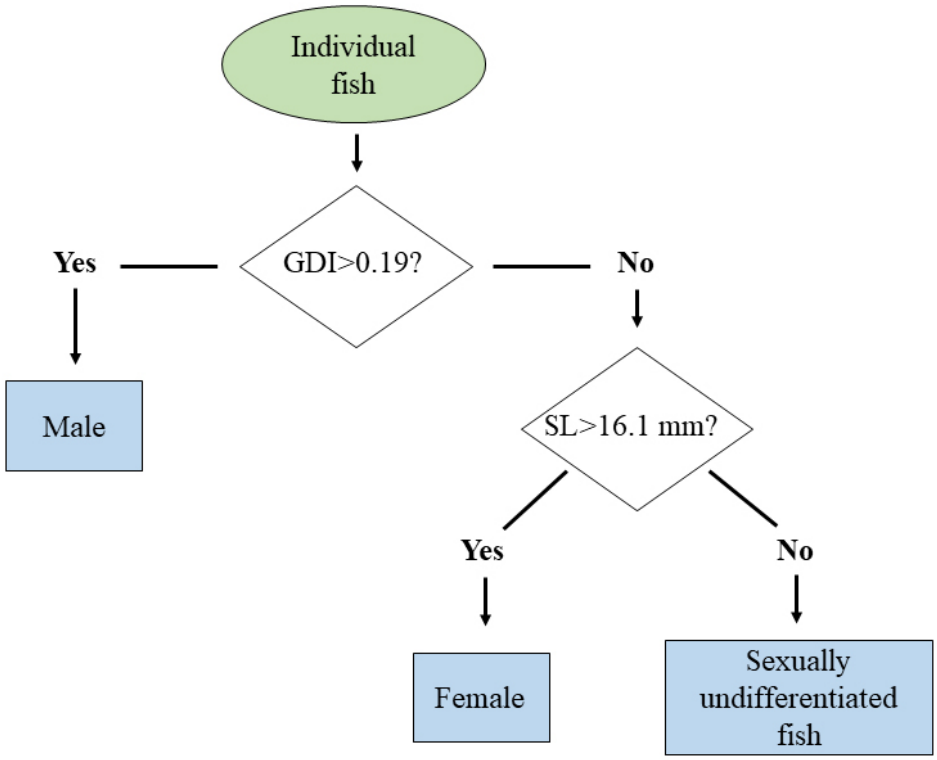

FIGURE 6 | Flow diagram for sexual group classification based on gonadal development, anal fin morphology, and body size. GDI: Gonopodium Development Index; SL: standard body length.

DISCUSSION

This study demonstrates for the first time that gonadal differentiation in *C. decemmaculatus* is already evident at birth in both sexes, with the testes and ovaries forming two distinct gonadal structures, as previously reported for other poeciliids (Kramer, 1985; Koya *et al.*, 2003; Razmi *et al.*, 2023; Uribe *et al.*, 2019). Similar patterns have been reported in the poeciliid *Gambusia holbrooki*, where early morphological differentiation of the ovary and testis is accompanied by sex-specific expression of genes involved in gonadal differentiation, including *foxl2* and *cyp19a1a* in females, and *dmrt1* and *amh* in males (Razmi *et al.*, 2023). Although molecular markers were not evaluated in the present study, the early histological differentiation observed in *C. decemmaculatus* suggests that comparable genetic pathways may underlie gonadal development in this species.

The organization of the testis germinal epithelium varies among teleost fishes, whose testes are lobular and classified into two types based on the distribution of spermatogonia: restricted and unrestricted (Grier *et al.*, 1980; Parenti, Grier, 2004; Uribe *et al.*, 2015). In atherinomorph fishes such as *C. decemmaculatus*, the restricted spermatogonial testis type is characterized by spermatogonia confined to the distal region of the testicular periphery and an orderly progression of germ cell development toward the efferent ducts (Uribe *et al.*, 2015). Although the paired testes fuse during development to form a single gonadal organ, the restricted spermatogonial type is

maintained, unlike the anastomosing tubular testes of basal teleost groups in which the sperm duct originates through the anastomosis of developing tubules (Mazzoni *et al*., 2014). Five stages of testicular development were identified in males of *C. decemmaculatus*. In early stages, sperm ducts were observed within each paired testicular structure, as previously reported during testicular development of *Gambusia affinis* (Koya *et al*., 2003). Sperm cysts developed from the testicular periphery to the central duct, and as spermatogenesis progresses, the increasing order of maturation occurs from spermatogonia to spermatozeugmata, a characteristic structure of the poeciliid testes that migrate towards the efferent ducts. It is consistent with the description reported by Grier (1975) in *Poecilia latipinna*. Lately, the presence of a pink colored substance located within the efferent ducts was observed, which is related to the PAS-positive secretion of a glycoprotein called pink-protein, secreted by the epithelium of the efferent ducts, according to Parenti *et al*. (2010). These authors argue that this protein is probably involved in sperm inactivation within the testis, preventing its final maturation. It is consistent with a mucoprotein secreted by the epithelial cells of the efferent ducts observed in *Poecilia mexicana* (Torres-Martínez *et al*., 2019) and *Poecilia latipinna* (Uribe *et al*., 2015). In addition, the production of this pink-protein can be inhibited by exposure to estrogenic compounds in *C. decemmaculatus* adult males (Young *et al*., 2017). In *C. decemmaculatus*, spermatozoa are organized within these sperm bundles with their heads oriented toward the periphery and their flagella directed toward the center, a pattern previously described in other poeciliid fish species such as *Poecilia latipinna*, *Gambusia affinis*, *Poecilia reticulata*, and *Phalloceros caudimaculatus* (Grier *et al*., 1975; Koya *et al*., 2003; Mazzoni *et al*., 2014; Uribe *et al*., 2015; Vicentini *et al*., 2010). Spermatozeugmata are eventually transferred from the male to the female during copulation. After insemination, these sperm bundles are dissociated within the female reproductive tract, allowing sperm activation and transport toward the ovary. Experimental studies in the viviparous goodeid *Xenotoca eiseni* have shown that spermatozeugmata remain intact during transfer but subsequently dissociate, releasing motile sperm capable of reaching the site of fertilization (Liu *et al*., 2018). This process suggests that sperm inactivation within the male reproductive tract may be functionally linked to the controlled activation and release of spermatozoa after copulation.

In teleosts, viviparity involves the ovary acting as a gestational organ. In poeciliids the ovary is cystovarian, organized as a single saccular structure with a central lumen (Uribe *et al*., 2019). In *C. decemmaculatus* females, the paired ovarian structures at birth already contain at least one primary oocyte, followed by a progressive centripetal proliferation of somatic cells toward the central septum (Stage 2). This group of cells finally converges, enclosing the ovarian cavity while the cells of the septum are reabsorbed, resulting in a single saccular ovary. A similar somatic cell growth leading to an ovarian cavity was also described in other fish species, such as *G. holbrooki* (Razmi *et al*., 2023), *Odontesthes bonariensis* (Ito *et al*., 2005) and *Tilapia mossambica* (Nakamura, 2013). Within the ovary, the different stages of oocyte development are distributed around the ovarian cavity. In general, oogonia are located close to this cavity, as reported for other poeciliid species such as *Heterandria formosa* (Uribe *et al*., 2019). No clear spatial organization of the different oocyte developmental stages was observed. At the end of development, a single ovary occupying a large portion of the body cavity was observed, as previously reported by Young *et al*. (2020). In several poeciliid species,

mature females possess ovarian sperm-storage structures (spermathecae), formed by folds of ovarian tissue that surround spermatozoa and may maintain their viability for prolonged periods within the female reproductive tract (Olivera-Tlahuel *et al*., 2017). These structures could facilitate the long-term storage of sperm following copulation and provide a continuous supply of viable spermatozoa for fertilization.

For the study of anal fin morphogenesis, the development of the *G. affinis* gonopodium reported by Turner (1941) was taken as a basis due to the close phylogenetic relationship between this species and *C. decemmaculatus*. In *G. affinis*, males can be distinguished from females by the length of the 3–5 anal fin rays (Rosa-Molinar *et al*., 1996). Adult males can be distinguished from juvenile males by the progressive transformation of the anal fin into a functional gonopodium during sexual maturation (Turner, 1941; Ghedotti, 2000). The morphological changes that the anal fin undergoes determine the main secondary sexual character that allows the differentiation between both sexes in *C. decemmaculatus*. The systematic recording of the quantitative and qualitative morphological variables made possible to describe the anal fin morphogenesis. The main parameters used to characterize gonopodial development and differentiate between males and females were the length of the 4th and 6th anal fin rays, the gonopodial index, and the elongation index. The importance of the elongation index was originally proposed by Angus *et al*. (2001) in *G. affinis* and later used by Doyle, Lim (2002) in *G. holbrooki*. Brockmeier *et al*. (2013) subsequently used this index to demonstrate that the anabolic-androgenic steroid 17β-trenbolone induces anal fin elongation in both *G. affinis* and *G. holbrooki.* The correlation between this variable and the gonopodial index, added to other qualitative morphological parameters, allowed the differentiation into four stages of gonopodial development in *C. decemmaculatus*.

At the undifferentiated anal fin stage, the sexes are not visually distinguishable, and the anal fin comprises 10 rays, as reported by Lucinda, Reis (2005). Then, a thickening of the third ray and the elongation of the third, fourth, and fifth rays are the first morphological changes, similarly to the process in *G. affinis* (Turner, 1941). Later, the ankylosis at the base of the rays, the complete ossification, and the appearance of serraes, hook, and cirrus at the distal end complete the gonopodial maturity, enabling it for copulation (Turner, 1941). Based on the use of the length of the fourth ray of the anal fin, GI, and EI, the first indications of sexual dimorphism were observed from 9.32 and 16.1 mm of SL, as well as from 13.2 and 70.6 mg of body weight for *C. decemmaculatus* males and females, respectively. In this sense, the male phenotype can be unequivocally identified before female phenotype due to the external appearance of the gonopodial primordium. Therefore, males could be externally identified when fish reach GI values > 21% and EI > 1.25.

The association between gonadal development and the onset of secondary sexual characteristics provides insight into the processes underlying sexual development and suggests potential physiological and molecular mechanisms. In the present study, the gonads are differentiated at birth, whereas the anal fin remains undifferentiated. In other poeciliids, several authors have studied the molecular mechanisms involved in the morphogenesis of secondary sexual characteristics (Zauner *et al*., 2003; Ogino *et al*., 2004, 2011, 2014, 2018; Offen *et al*., 2008, 2009, 2013). Moreover, gonadal development (Van den Hurk, 1974), anal fin morphogenesis (Kramer, Kallman, 1985), and their relationship (Schreibman *et al*., 1982) were described for this group. For

instance, androgen receptors (ARα and ARβ) are expressed in the distal portion of anal fin rays during gonopodial morphogenesis, and sonic-hedgehog gene (*shh*) expression induces elongation of this structure in *G. affinis* (Ogino *et al*., 2004, 2011). Androgen levels and *shh* expression regulate cell proliferation, contributing to the development of new bone segments during gonopodial morphogenesis (Ogino *et al*., 2018).

The GDI enables estimation of gonopodium development independently of age and showed 100% effectiveness in validating the threshold values separating the proposed stages. GDI is calculated using the values of three quantitative (length of the fourth and sixth rays of the gonopodium, and the standard length) and two qualitative parameters (presence or absence of the gonopodial primordium, and of serraes, hook, and cirrus in the distal end of the anal fin). Furthermore, sexually undifferentiated fish showed GDI values statistically similar to those of the female phenotype.

The present study shows that GDI may provide a useful indicator in studies conducted under natural conditions, as it is independent of age. Age-related data showed greater variability, preventing a clear determination of when males and females can be externally distinguished. Consistent with previous studies, development was more strongly associated with body size than with age (Fuiman *et al*., 1998; Adriaens, Verraes, 2002; Sæle, Pittman, 2010; Chalde *et al*., 2011).

The present study demonstrated a balanced sex ratio, providing a useful reference for evaluating fish exposure to endocrine-disrupting chemicals. For example, Young *et al*. (2020) found a greater proportion of females than males *C. decemmaculatus* exposed chronically to 17α-ethinylestradiol, a synthetic estrogen. In future studies, GDI could be used as a biomonitoring tool of aquatic ecosystems and applied to other species of poeciliids.

In conclusion, this study demonstrates for the first time in *Cnesterodon decemmaculatus* that individuals are already sexually differentiated at birth, with ovaries and testes clearly distinguishable by gonadal histology, although not by external morphology. During postnatal development, males can be readily identified by the growth of the gonopodial primordium, whereas females remain externally indistinguishable for a longer period.

The proposed Gonopodium Development Index (GDI) enables unambiguous discrimination between males and females once individuals exceed a standard length of 16.1 mm and provides a practical metric for quantifying gonopodium morphogenesis independently of age. Beyond its relevance for understanding sexual development in this species, the GDI represents a useful tool for studies of reproductive biology and for applications in aquatic biomonitoring.

REFERENCES

- **Adriaens D, Verraes W.** An empirical approach to study the relation between ontogeny, size and age using geometric morphometrics. In: Aerts P, D'Août K, Herrel A, Van Damme R, editors. Topics in functional and ecological vertebrate morphology. Maastricht: Shaker Publishing; 2002. p.293–324.
- **Angus RA, McNatt HB, Howell WM, Peoples SD.** Gonopodial development in normal male and 11-ketotestosterone-treated female mosquitofish (*Gambusia affinis*): a quantitative study using computer image analysis. Gen Comp Endocrinol. 2001; 123(2):222–34. https://doi.org/10.1006/gcen.2001.7669

- **Angus RA, Stanko J, Jenkins RL, Watson RD.** Effects of 17α-ethynylestradiol on sexual development of male western mosquitofish (*Gambusia affinis*). Comp Biochem Physiol. 2005; 140C(3–4):330–39. https://doi.org/10.1016/j.cca.2005.03.008
- **Baudou FG, Eissa BL, Ossana NA, Mastrángelo MM, Ferro JP, Campos LB *et al*.** First baseline for bioenergetic biomarkers in *Cnesterodon decemmaculatus* as test organism in ecotoxicological studies. Ecotoxicol Environ Saf. 2021; 208:111639. https://doi.org/10.1016/j.ecoenv.2020.111639
- **Blasco M, Somoza GM, Vizziano-Cantonnet D.** Presence of 11-ketotestosterone in pre-differentiated male gonads of *Odontesthes bonariensis*. Fish Physiol Biochem. 2013; 39:71–74. https://doi.org/10.1007/s10695-012-9651-z
- **Brockmeier EK, Ogino Y, Iguchi T, Barber DS, Denslow ND.** Effects of 17β-trenbolone on Eastern and Western mosquitofish (*Gambusia holbrooki* and *G. affinis*) anal fin growth and gene expression patterns. Aquatic Toxicol. 2013; 128–29:163–70. https://doi.org/10.1016/j.aquatox.2012.12.007
- **Candioti JV, Soloneski S, Larramendy ML.** Genotoxic and cytotoxic effects of the formulated insecticide Aficida® on *Cnesterodon decemmaculatus* (Jenyns, 1842) (Pisces: Poeciliidae). Mutat Res. 2010; 703(2):180–86. https://doi.org/10.1016/j.mrgentox.2010.08.018
- **Carriquiriborde P, Díaz J, Mugni H, Bonetto C, Ronco AE.** Impact of cypermethrin on stream fish populations under field-use in biotech-soybean production. Chemosphere. 2007; 68(4):613–21. https://doi.org/10.1016/j.chemosphere.2007.02.051
- **Castañeda-Cortés DC, Zhang J, Boan AF, Langlois VS, Fernandino JI.** High temperature stress response is not sexually dimorphic at the whole-body level and is dependent on androgens to induce sex reversal. Gen Comp Endocrinol. 2020; 299:113605. https://doi.org/10.1016/j.ygcen.2020.113605
- **Chalde T, Fernández DA, Cussac VE, Somoza GM.** The effect of rearing temperature in larval development of pejerrey, *Odontesthes bonariensis*: morphological indicators of development. Neotrop Ichthyol. 2011; 9(4):747–56. https://doi.org/10.1590/S1679-62252011005000040
- **Devlin RH, Nagahama Y.** Sex determination and sex differentiation in fish: an overview of genetic, physiological, and environmental influences. Aquaculture. 2002; 208(3–4):191–364. https://doi.org/10.1016/S0044-8486(02)00057-1
- **Doyle CJ, Lim R.** The effect of 17β-estradiol on the gonopodial development and sexual activity of *Gambusia holbrooki*. Environ Toxicol Chem. 2002; 21(12):2719–24. https://doi.org/10.1002/etc.5620211227
- **Fernandino JI, Hattori RS, Kishii A, Strüssmann CA, Somoza GM.** The cortisol and androgen pathways cross talk in high temperature-induced masculinization: the 11β-hydroxysteroid dehydrogenase as a key enzyme. Endocrinology. 2012; 153(12):6003–11. https://doi.org/10.1210/en.2012-1517
- **Fuiman LA, Poling KR, Higgs DM.** Quantifying developmental progress for comparative studies of larval fishes. Copeia. 1998; 1998(3):602–11. https://doi.org/10.2307/1447790
- **Ghedotti MJ.** Phylogenetic analysis and taxonomy of the poecilioid fishes (Teleostei: Cyprinodontiformes). Zool J Linnean Soc. 2000; 130(1):1–53. https://doi.org/10.1111/j.1096-3642.2000.tb02194.x
- **Grier JH.** Aspects of germinal cyst and sperm development in *Poecilia latipinna* (Teleostei: Poeciliidae). J Morphol. 1975; 146:229–49. https://doi.org/10.1002/jmor.1051460205
- **Grier H, Linton J, Leatherland J, De Vlaming V.** Structural evidence for two different testicular types in teleost fishes. Am J Anat. 1980; 159:331–45. https://doi.org/10.1002/aja.1001590307
- **Hrbek T, Seckinger J, Meyer A.** A phylogenetic and biogeographic perspective on the evolution of poeciliid fishes. Mol Phylogenet Evol. 2007; 43(3):986–98. https://doi.org/10.1016/j.ympev.2006.06.009
- **Huang GY, Fang GZ, Shi WJ, Li XP, Wang CS, Chen HX *et al*.** Interaction of 17α-ethinylestradiol and methyltestosterone in western mosquitofish (*Gambusia affinis*) across two generations. Aquat Toxicol. 2024; 268:106854. https://doi.org/10.1016/j.aquatox.2024.106854

- **Ito LS, Yamashita M, Takashima F, Strüssmann CA.** Dynamics and histological characteristics of gonadal sex differentiation in pejerrey (*Odontesthes bonariensis*) at feminizing and masculinizing temperatures. J Exp Zool. 2005; 303A(6):504–14. https://doi.org/10.1002/jez.a.159
- **Jackson LM, Felgenhauer BE, Klerks PL.** Feminization, altered gonadal development, and liver damage in least killifish (*Heterandria formosa*) exposed to sublethal concentrations of 17α-ethinylestradiol. Ecotoxicol Environ Saf. 2019; 170:331–37. https://doi.org/10.1016/j.ecoenv.2018.11.094
- **Koya Y, Fujita A, Niki F, Ishihara E, Miyama H.** Sex differentiation and pubertal development of gonads in the viviparous mosquitofish, *Gambusia affinis*. Zool Sci. 2003; 20(10):1231–42. https://doi.org/10.2108/zsj.20.1231
- **Kramer CR, Kallman KD.** Sex differentiation of somatic tissue in the unsexualised gonad primordia of the embryos of three species of poeciliid fish. J Anat. 1985; 140(Pt 2):269–77.
- **Liu Y, Yang H, Torres L, Tiersch TR.** Activation of free sperm and dissociation of sperm bundles (spermatozeugmata) of an endangered viviparous fish, *Xenotoca eiseni*. Comp Biochem Physiol A Mol Integr Physiol. 2018; 218:35–45. https://doi.org/10.1016/j.cbpa.2018.01.006
- **Lubzens E, Young G, Bobe J, Cerdà J.** Oogenesis in teleosts: how fish eggs are formed. Gen Comp Endocrinol. 2010; 165(3):367–89. https://doi.org/10.1016/j.ygcen.2009.05.022
- **Lucinda PHF, Reis RE.** Systematics of the subfamily Poeciliinae Bonaparte (Cyprinodontiformes: Poeciliidae), with an emphasis on the tribe Cnesterodontini Hubbs. Neotrop Ichthyol. 2005; 3(1):1–60. https://doi.org/10.1590/S1679-62252005000100001
- **Mazzoni TS, Grier HJ, Quagio-Grassiotto I.** Male gonadal differentiation and the paedomorphic evolution of the testis in Teleostei. Anat Rec. 2014; 297:1137–62. https://doi.org/10.1002/ar.22915
- **Mei J, Gui JF.** Genetic basis and biotechnological manipulation of sexual dimorphism and sex determination in fish. Sci China Life Sci. 2015; 58:124–36. https://doi.org/10.1007/s11427-014-4797-9
- **Nagahama Y, Chakraborty T, Paul-Prasanth B, Ohta K, Nakamura M.** Sex determination, gonadal sex differentiation, and plasticity in vertebrate species. Physiol Rev. 2020; 101(3):1237–308. https://doi.org/10.1152/physrev.00044.2019
- **Nakamura M.** Morphological and physiological studies on gonadal sex differentiation in teleost fish. ABSM. 2013; 6(1):1–47.
- **Offen N, Blum N, Meyer A, Begemann G.** *Fgfr1* signalling in the development of a sexually selected trait in vertebrates, the sword of swordtail fish. BMC Dev Biol. 2008; 8(98):1–18. https://doi.org/10.1186/1471-213X-8-98
- **Offen N, Kang JH, Meyer A, Begemann G.** Retinoic acid is involved in the metamorphosis of the anal fin into an intromittent organ, the gonopodium, in the green swordtail (*Xiphophorus hellerii*). PLoS ONE. 2013; 8(10):e77580. https://doi.org/10.1371/journal.pone.0077580
- **Offen N, Meyer A, Begemann G.** Identification of novel genes involved in the development of the sword and gonopodium in swordtail fish. Dev Dyn. 2009; 238(7):1674–87. https://doi.org/10.1002/dvdy.21983
- **Ogino Y, Hirakawa I, Inohaya K, Sumiya E, Miyagawa S, Denslow N *et al.*** Bmp7 and Lef1 are the downstream effectors of androgen signaling in androgen-induced sex characteristics development in medaka. Endocrinology. 2014; 155(2):449–62. https://doi.org/10.1210/en.2013-1507
- **Ogino Y, Katoh H, Yamada G.** Androgen dependent development of a modified anal fin, gonopodium, as a model to understand the mechanism of secondary sexual character expression in vertebrates. FEBS letters. 2004; 575(1–3):119–26. https://doi.org/10.1016/j.febslet.2004.08.046
- **Ogino Y, Miyagawa S, Katoh H, Prins GS, Iguchi T, Yamada G.** Essential functions of androgen signaling emerged through the developmental analysis of vertebrate sex characteristics. Evol Dev. 2011; 13(3):315–25. https://doi.org/10.1111/j.1525-142X.2011.00482.x

- **Ogino Y, Tohyama S, Kohno S, Toyota K, Yamada G, Yatsu R *et al*.** Functional distinctions associated with the diversity of sex steroid hormone receptors ESR and AR. J Steroid Biochem Mol Biol. 2018; 184:38–46. https://doi.org/10.1016/j.jsbmb.2018.06.002
- **Olivera-Tlahuel C, Villagrán-Santa Cruz M, Moreno-Mendoza NA, Zúñiga-Vega JJ.** Morphological structures for potential sperm storage in poeciliid fishes. Does superfetation matter? J Morphol. 2017; 278(7):907–18. https://doi.org/10.1002/jmor.20684
- **Paracampo A, Marrochi N, García I, Maiztegui T, Carriquiriborde P, Bonetto C *et al*.** Fish assemblages of Pampean streams (Buenos Aires, Argentina): relationships with abiotic and anthropogenic variables. An Acad Bras Ciênc. 2020; 92(2):e20190476. https://doi.org/10.1590/0001-3765202020190476
- **Parenti LR, Grier HJ.** Evolution and phylogeny of gonad morphology in bony fishes. Integr Comp Biol. 2004; 44(5):333–48. https://doi.org/10.1093/icb/44.5.333
- **Parenti LR, Lo Nostro FL, Grier HJ.** Reproductive histology of *Tomeurus gracilis* Eigenmann, 1909 (Teleostei: Atherinomorpha: Poeciliidae) with comments on evolution of viviparity in atherinomorph fishes. J Morphol. 2010; 271(11):1399–406. https://doi.org/10.1002/jmor.10886
- **Ramos-Fregonezi AMC, Malabarba LR, Fagundes NJR.** Population genetic structure of *Cnesterodon decemmaculatus* (Poeciliidae): a freshwater look at the Pampa biome in southern South America. Front Genet. 2017; 8:214. https://doi.org/10.3389/fgene.2017.00214
- **Razmi K, Tran NK, Patil JG.** Gonad ontogeny and sex differentiation in a poeciliid, *Gambusia holbrooki*: Transition from a bi- to a mono-lobed organ. Biology. 2023; 12(5):731. https://doi.org/10.3390/biology12050731
- **Rosa-Molinar E, Fritzsch B, Hendricks SE.** Organizational-activational concept revisited: sexual differentiation in an atherinomorph teleost. Horm Behav. 1996; 30(4):563–75. https://doi.org/10.1006/hbeh.1996.0059
- **Sæle Ø, Pittman KA.** Looking closer at the determining of a phenotype? Compare by stages or size, not age. J Appl Ichthyol. 2010; 26:294–97. https://doi.org/10.1111/j.1439-0426.2010.01424.x
- **Santamaría-Martín CJ, Plaul SE, Campuzano Caballero JC, Uribe MC, Barbeito CG.** Structure of the gonoduct of the viviparous teleost *Cnesterodon decemmaculatus* (Jenyns, 1842) (Poeciliidae). J Morphol. 2021; 282(4):533–42. https://doi.org/10.1002/jmor.21326
- **Schreibman MP, Berkowitz EJ, Van den Hurk R.** Histology and histochemistry of the testis and ovary of the platyfish, *Xiphophorus maculatus*, from birth to sexual maturity. Cell Tissue Res. 1982; 224:81–87. https://doi.org/10.1007/bf00217268
- **Schulz RW, França LR, Lareyre J-J, Le Gac F, Chiarini-Garcia H, Nóbrega RH *et al*.** Spermatogenesis in fish. Gen Comp Endocrinol. 2010; 165(3):390–411. https://doi.org/10.1016/j.ygcen.2009.02.013
- **Siccardi EM.** La reproducción de los Cyprinodontiformes. Ichthys. 1955; 1(4):137–44.
- **Sotelo JR, Trujillo-Cenóz O.** Electron microscope study of the kinetic apparatus in animal sperm cells. Z Zellforsch Mikrosk Anat. 1958; 48:565–601. https://doi.org/10.1007/bf00342732
- **Torres-Martínez A, Ruiz de Dios L, Hernández-Franyutti A, Uribe MC, Contreras Sánchez W.** Structure of the testis and spermatogenesis of the viviparous teleost *Poecilia mexicana* (Poeciliidae) from an active sulfur spring cave in Southern Mexico. J Morphol. 2019; 280(10):1537–47. https://doi.org/10.1002/jmor.21047
- **Trudeau V.** Neuroendocrine control of reproduction in teleost fish: Concepts and controversies. Annu Rev Anim Biosci. 2022; 10:107–30. https://doi.org/10.1146/annurev-animal-020420-042015
- **Turner CL.** Morphogenesis of the gonopodium in *Gambusia affinis affinis*. J Morphol. 1941; 69(1):161–85. https://doi.org/10.1002/jmor.1050690107

- **Uribe MC, Rosa Cruz G, García Alarcón A, Campuzano Caballero JC, Guzmán Bárcenas MG.** Structures associated with oogenesis and embryonic development during intraovarian gestation in viviparous teleosts (Poeciliidae). Fishes. 2019; 4(2):35. https://doi.org/10.3390/fishes4020035
- **Uribe MC, Grier HJ, Mejia-Roa V.** Comparative testicular structure and spermatogenesis in bony fishes. Spermatogenesis. 2015; 4(3):e983400. https://doi.org/10.4161/21565562.2014.983400
- **Van den Hurk R.** Steroidogenesis in the testis and gonadotropic activity in the pituitary during postnatal development of the black molly (*Mollienisia latipinna*). K Ned Akad Wet C. 1974; 77(2):193–200.
- **Vicentini CA, Muñoz ME, Vicentini IBF.** Ultrastructural aspects of spermatogenesis in *Phalloceros caudimaculatus* (Teleostei, Poeciliidae). Int J Morphol. 2010; 28(3):951–56. https://doi.org/10.4067/S0717-95022010000300047
- **Vidal N, Loureiro M, Hued AC, Eguren G, Texeira de Mello F.** Female masculinization and reproductive success in *Cnesterodon decemmaculatus* (Jenyns, 1842) (Cyprinodontiforme: Poeciliidae) under anthropogenic impact. Ecotoxicology. 2018; 27:1331–40. https://doi.org/10.1007/s10646-018-1985-6
- **Vissio PG, Di Yorio MP, Pérez-Sirkin DI, Somoza GM, Tsutsui K, Sallemi JE.** Developmental aspects of the hypothalamic-pituitary network related to reproduction in teleost fish. Front Neuroendocrinol. 2021; 63:100948. https://doi.org/10.1016/j.yfrne.2021.100948
- **Young BJ, Cristos DS, Crespo DC, Somoza GM, Carriquiriborde P.** Effects of 17α-ethinylestradiol on sex ratio, gonadal histology and perianal hyperpigmentation of *Cnesterodon decemmaculatus* (Pisces, Poeciliidae) during a full-lifecycle exposure. Ecotoxicol Environ Saf. 2020; 205:111176. https://doi.org/10.1016/j.ecoenv.2020.111176
- **Young BJ, Lopez GC, Cristos DS, Crespo DC, Somoza GM, Carriquiriborde P.** Intersex and liver alterations induced by long-term sublethal exposure to 17α-ethinylestradiol in adult male *Cnesterodon decemmaculatus* (Pisces: Poeciliidae). Environ Toxicol Chem. 2017; 36(7):1738–45. https://doi.org/10.1002/etc.3547
- **Zambrano MJ, Bonifacio AF, Brito JM, Rautenberg GE, Hued AC.** Length-weight relationships and body condition indices of a South American bioindicator, the native Neotropical fish species, *Cnesterodon decemmaculatus* (Poeciliidae). J Ichthyol. 2023; 63:930–36. https://doi.org/10.1134/S0032945223050156
- **Zhang S, Li X, Li X, Wang X, Ru S, Tian H.** 17β-Trenbolone activates androgen receptor, upregulates transforming growth factor beta/bone morphogenetic protein and Wnt signaling pathways, and induces masculinization of caudal and anal fins in female guppies (*Poecilia reticulata*). Aquat Toxicol. 2023; 263:106677. https://doi.org/10.1016/j.aquatox.2023.106677
- **Zohar Y.** Fish reproductive biology-reflecting on five decades of fundamental and translational research. Gen Comp Endocrinol. 2021; 300:113544. https://doi.org/10.1016/j.ygcen.2020.113544
- **Zauner H, Begemann G, Mari-Beffa M, Meyer A.** Differential regulation of *msx* genes in the development of the gonopodium, an intromittent organ, and of the "sword" a sexually selected trait of swordtail fishes (*Xiphophorus*). Evol Dev. 2003; 5(5):466–77. https://doi.org/10.1046/j.1525-142X.2003.03053.x

AUTHORS' CONTRIBUTION

Brian Jonathan Young: Conceptualization, Formal analysis, Investigation, Methodology, Visualization, Writing-original draft, Writing-review and editing.
Gabriela Carina López: Investigation, Methodology, Resources.
Diana Cristina Crespo: Funding Acquisition, Project administration, Resources.
Pedro Carriquiriborde: Conceptualization, Funding acquisition, Methodology, Project administration, Resources, Supervision, Visualization, Writing-review and editing.
Gustavo Manuel Somoza: Conceptualization, Funding acquisition, Methodology, Project administration, Resources, Supervision, Visualization, Writing-review and editing.

FUNDING INFORMATION

The study was funded by the PNNAT Project from INTA Nº 1128042 to DCC, and the PICT Projects from ANPCyT Nº 38206 and 1383 to PC and GMS respectively.

ETHICAL STATEMENT

Experiments were conducted following the principles and procedures approved by the Institutional Committee for the Care and Use of Experimental Animals of the Research Center in Veterinary and Agronomic Sciences (CICVyA)-INTA (Hurlingham, Argentina), under the procedure number 60/year 2016.

DATA AVAILABILITY STATEMENT

The data supporting the findings of this study are available from the corresponding author upon reasonable request.

AI STATEMENT

The authors did not use any AI-assisted technologies in the creation of this manuscript or its figures.

COMPETING INTERESTS

The authors declare no competing interests.

SUPPLEMENTARY MATERIAL

Supplementary Material File

PEER REVIEW REPORT

Reviewers:
Anonymous reviewer #1
Anonymous reviewer #2
The peer review report is available at: Neotropical Ichthyology

HOW TO CITE THIS ARTICLE

- **Young BJ, López GC, Crespo DC, Carriquiriborde P, Somoza GM.** Gonadal development and anal fin morphogenesis in *Cnesterodon decemmaculatus* (Cyprinodontiformes: Poeciliidae). Neotrop Ichthyol. 2026; 24(4):e260038. https://doi.org/10.1590/1982-0224-2026-0038

Neotropical Ichthyology

OPEN ACCESS

This is an open access article under the terms of the Creative Commons Attribution License, which permits use, distribution and reproduction in any medium, provided the original work is properly cited.

Distributed under
Creative Commons CC-BY 4.0

© 2026 The Authors.
Published by SBI

SBI | Official Journal of the Sociedade Brasileira de Ictiologia